

# ENDOMETRIAL HISTOLOGICAL CHANGES AND PREGNANCY RATES IN MARES IMPAIRED CERVICAL DRAINAGE

**Evija Liepina, Vita Antane**

LUA, Faculty of Veterinary Medicine, Latvia

[evija\\_liepina@inbox.lv](mailto:evija_liepina@inbox.lv)

## ABSTRACT

Patency of the cervix of the mare is considered to be a prerequisite for efficient uterine drainage after mating. Endometriosis, also known as chronic degenerative endometritis, is described a periglandular and/ or stromal endometrial fibrosis, including glandular alteration in fibrotic foci. Endometrial fibrosis, a major cause of reduced reproductive efficiency in mares, is a progressive and irreversible condition which tends to worsen with age. The aim of the study is to evaluate biopsy specimens from endometrium obtained during the first and fifth oestrus to determine initial microscopic status of endometrium and any changes in the endometrium that may have happened as a result of occluded cervix and analyze pregnancy rates after the experiment. A total of 24 cycling light breed mares from MTT Agrifood Research and Equine College, Ypaja, Finland, were used in the study. The study was designed as a cross-over study where each mare received two treatments one of which was control treatment thus serving as internal control. The mares were observed during 5 oestrus periods and during two of these periods (second and fourth oestrus) the treatment was applied. According to the closing and opening of the cervix which was regulated using Bivona catheter, mares were distributed in 3 treatments. TRT A -- intrauterine catheter closed for 25 h; TRT B - - intrauterine catheter closed for 6h+19 h (catheter closed for 6h, opened and fluid collected; catheter for closed for another 19h); TRT C (control) - no intrauterine catheter. The results shows that occlusion of the cervix might influence the pregnancy rates since the uterus could not clear itself from inflammatory cells such as polymorphonuclear leukocytes. The impairment of uterine drainage increased periglandular fibrosis in endometrium and decreased pregnancy rates.

**KEY WORDS:** endometriosis, mare, biopsy, inflammation, fibrosis.

## INTRODUCTION

Patency of the cervix of the mare is considered to be a prerequisite for efficient uterine drainage after mating. If the cervix fails to open adequately, post-breeding endometritis will not resolve within 24 hours, as it should be in normal mares, but fluid, PMNs and cytokines will accumulate in the uterus. Reduced myometrial contractions, poor lymphatic drainage, large and overstretched uterus and cervical incompetence are predisposing factors for persistent mating-induced endometritis.

Endometriosis, also known as chronic degenerative endometritis, is described a periglandular and/ or stromal endometrial fibrosis, including glandular alteration in fibrotic foci (Hofman et al., 2003). Endometrial fibrosis, a major cause of reduced reproductive efficiency in mares, is a progressive and irreversible condition which tends to worsen with age. It is aggravated by frequent endometrial challenges such as breeding and infection (Ricketts and Alonso, 1991). The fibrosis reduces the efficacy of uterine defence mechanisms and the uterine capacity for foetal nutrition (Oddsdottir C. et al., 2008). Embryonic and fetal loss from endometria with widespread periglandular

fibrosis has been observed and it has been considered to be the major diagnosable case of this type of reproductive failure. Any injury that causes an inflammatory reaction may induce fibrosis.

Endometrial biopsy is evolving as a useful technique for aiding in the diagnosis and prognosis of the endometrium's ability to carry a foal to term, and it plays an important role in fertility examination of the mare. It also helps the diagnosis of endometritis when clinical findings and culture results are not definite (Colahan et.al.,1999).

The aim of the study is to evaluate biopsy specimens from endometrium obtained during the first and fifth oestrus to determine initial microscopic status of endometrium and any changes in the endometrium that may have happened as a result of occluded cervix and analyze pregnancy rates after the experiment.

## **MATERIALS AND METHODS**

A total of 24 cycling light breed mares from MTT Agrifood Research and Equine College, Ypaja, Finland, were used in the study. Mares were 3–17 years old (mean 9.6 years), had no history of reproductive failure and were clinically healthy. This study was carried out from the beginning of April to early September 2007.

The study was designed as a cross-over study where each mare received two treatments one of which was control treatment thus serving as internal control. The mares were observed during 5 oestrus periods and during two of these periods (second and fourth oestrus) the treatment was applied. Treatments were as follows: Treatment A (TRT A) -- intrauterine catheter closed for 25 h, immediately after artificial insemination (AI) and occluded 65 –cm, 33fr diameter Bivona catheter (Equivet, Kruuse, Marslev, Denmark) was inserted into the uterus and the cuff was filled with a 80-ml of air. The catheter was occluded at the end opposite to the cuff so that no fluid could escape from the catheter. After 25h the catheter was opened and the fluid drained into a sterile Falcon cylinder. Treatment B (TRT B) -- intrauterine catheter closed for 6h+19 h, immediately after AI and a Bivona catheter was inserted as described for TRT A. The catheter was opened after 6h and fluid drained into a sterile Falcon cylinder. Then catheter was closed for another 19h after which it was opened and fluid collected as described above. Treatment C (TRT C) – control, no intrauterine catheter. A sterilized, regular-sized tampon (Tampax Inc., Palmer, MA, USA) with a long cotton string was placed within a 45-cm long plastic or metal tube which was inserted into the uterus by manual guidance through the cervix 25h after AI. A 53.5 cm long plastic AI catheter was used to push the tampon inside the uterus while the tube was withdrawn. After 20 minutes the tampon was removed through a sterilized speculum. Fluid absorbed into the tampon was squeezed out into a sterile plastic Falcon tube with a sterile garlic press.

For mares of all treatment groups uterine lavage was performed using 500 ml Ringer's solution (Ringer-Acetate Viaflo, Baxter) after the last manipulation (collection of intrauterine fluid in TRT A, TRT B and TRT C mares). All mares were given 10 IU oxytocin i/v during or after lavage. Mares were randomly assigned to 1 of 4 groups; group 1 (TRT C/A)- mares at the second oestrus was control (C) but at the fourth oestrus the same group received treatment A, group 2 (TRT A/C)- mares at the second oestrus received treatment A but at the fourth oestrus the same group was control, group 3 (TRT C/B)- mares at the second oestrus was control but at the fourth oestrus the same group received treatment B, group 4 (TRT B/C)- mares at the second oestrus received treatment B but at the fourth oestrus the same group was control.

Oestrus was synchronised with 0.25 mg cloprostenol i/m (Estrumate vet., Schering-Plough A/S Farum, Denmark). The mares were examined by transrectal palpation and

ultrasonography (Sono Site Vet 180 plus with a 5- MHz probe; Sono Site Inc., Bothell, WA, USA) on Monday, Wednesday and Friday. Relaxation of the cervix, the number and size of follicles, corpus luteum and the degree of endometrial oedema were assessed. It was presumed that the mare was in oestrus when a pre-ovulatory follicle of  $\geq 35$ mm was detected in association with uterine oedema and cervical softening. An approximate assessment of the amount of uterine fluid was made by measuring ultrasonographically the depth and length (height (mm) x width (mm)) of any pools of fluid in the uterus at the time of oestrus.

During the second and fourth oestrus mares were inseminated with pooled semen from 2 stallions using a standard AI catheter. Semen was collected using an automated phantom (Equidame®) and diluted with skim milk extender to get an insemination dose of  $500 \times 10^6$  progressively motile spermatozoa in a volume of 20 ml ( $250 \times 10^6$  from each stallion). All mares received an intravenous injection of 1500 IU of human chorionic gonadotrophin (hCG, Chorulon®, Intervet International B.V., Boxmeer, The Netherlands) right after AI to synchronize ovulation. Palpation and ultrasonographic examination continued daily until ovulation was detected.

Pregnancy examination was done 15 – 17 days after AI by ultrasonography. Pregnant mares received 0.25 mg cloprostenol i.m (Estrumate vet., Schering- Plough A/S Farum, Denmark) to terminate the pregnancy.

Biopsy specimens from endometrium were obtained during the first and fifth oestrus to determine initial microscopic status of endometrium and changes in the endometrium such as inflammation and periglandular fibrosis that may have happened as a result of impaired uterine drainage.

Endometrial biopsy specimens were obtained from the ventral wall at the base of either horn at first and fifth oestrus and processed as described by Kenney (1978). The histological slides were evaluated and categorized according to Kenney and Doig (1986).

The biopsy slides were scored from 0 to 5 for the degree of inflammation according to intensity of polymorphonuclear leukocytes (PMNs) and mononuclear cells (MNS): score 0- no cells, 1- small, insistent infiltration or slight diffuse under the epithelium, 2- smolish, relatively frequent infiltrations or a slight to moderate diffuse infiltration, 3- small to medium, frequent infiltrations or a moderate diffuse infiltration, 4- moderate or large, frequent infiltrations or a strong diffuse infiltrations, 5- the entire biopsy is covered by inflammatory cells. At the same time periglandular fibrosis was scored as follows: 0- none, 1- infrequent, slight <2/field, 2- moderately frequent, slight, 2-5/field, 3- frequent, slight to moderate, 6-10/field, 4- very frequent, moderate to large, >10 fibrotic nests per field and 5- all glands are affected.

All specimens from a mare were pooled for processing and evaluated without knowledge of their origin.

## RESULTS AND DISCUSSION

Table 1 explains the changes of inflammation and periglandular fibrosis in endometrial histological samples obtained pre- and post- experiment (1<sup>st</sup> and 5<sup>th</sup> oestrus). The value represent the percentage of mares with increased, decreased and the same status of degree of inflammation and periglandular fibrosis.

Table 1.

**Changes of inflammation and periglandular fibrosis in endometrial histological samples**

Inflammation score					Periglandular fibrosis			
	Group 1 (n=7) TRTC/A	Group 2 (n=6) TRTA/C	Group 3 (n=6) TRTC/B	Group 4 (n=4) TRTB/C	Group 1 (n=7) TRTC/A	Group 2 (n=6) TRTA/C	Group 3 (n=6) TRTC/B	Group 4 (n=4) TRTB/C
Increase	14.3	0	16.7	0	57.2	33.3	50	50
Decrease	42.9	0	50	50	0	16.7	16.7	0
The same	42.9	100	33.3	50	42.8	50	33.3	50

The increase of inflammation in mares endometrium compared with pre- and post-experiment were found in groups TRTC/A (14.3%) and group TRT C/B (16.7%). There was no increase in inflammation score in groups TRT A/C and group TRT C/B (0%). Half of the mares in all groups, except TRT A/C, had 50% decrease or remained the same inflammation score of pre and post experiment. At the same time all treatment groups showed an increase or with no changes (same) in periglandular fibrosis, except TRT A/C and TRT C/B where one mare in each group showed a decrease of periglandular fibrosis pre- and post- experiment. In general impaired uterine drainage did not increase inflammation score in endometrium pre- and post- experiment but there was an increase of periglandular fibrosis.

The pregnancy rates in mares with artificially occluded cervix are demonstrated in Table 2. As it was mentioned above each mare received two treatments one of which was control treatment thus serving as internal control.

Table 2.

**Pregnancy rates (%) after AI in 2nd and 4th oestrus period**

Group	Treatment	Pregnancy rate % after 2nd oestrus	Treatment	Pregnancy rate % after 4th oestrus
Group 1	TRT C	0 %	TRT A	14.3 %
Group 2	TRT A	66 %	TRT C	33.3 %
Group 3	TRT C	57 %	TRT B	0 %
Group 4	TRT B	50 %	TRT C	25 %

The results show that occlusion of the cervix might influence the pregnancy rates since the uterus could not clear itself from inflammatory cells such as polymorphonuclear leukocytes. None of the mare became pregnant from TRT C after the 2<sup>nd</sup> oestrus and TRT B after the 4<sup>th</sup> oestrus. At the same time, the same group had increased periglandular fibrosis in endometrium. In group 2 and 4 pregnancy rates after the 2<sup>nd</sup> oestrus were 66% and 50% and after the 4<sup>th</sup> oestrus pregnancy rates were decreased for 50 % (33.3% and 25%). Group 2 and 4 like group 1 and 3 had increased periglandular fibrosis in endometrium. It seems likely that occlusion of the cervix and increased periglandular fibrosis in endometrium has influenced the pregnancy rates. The influx of polymorphonuclear neutrophils (PMN) starts approximately 30 min after AI (Katila, 1995) and the peak of endometrial inflammation is reached 6 to 24 h post breeding. If the uterine clearance fails, pregnancy rates are reduced (Adams et al.,

1987). Reduced myometrial contractions, poor lymphatic drainage, large and overstretched uterus and cervical incompetence are predisposing factors for persistent mating-induced endometritis and, as Troedsson (1997) suggests, inflammation, especially repeated inflammation may result in degenerative changes of the endometrium and early embryonic death.

Pregnancy rates in all mares (Fig.1) were 2.5 times smaller after the 4th oestrus period (16.7%) than after the 2nd oestrus period (41.7%). These results also suggest that impaired uterine drainage affects the pregnancy rates.

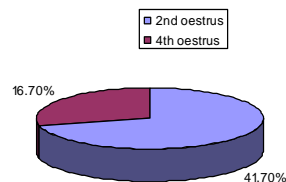


Figure 1. Pregnancy rates (%) in all mares after the 2nd and 4th oestrus period

## CONCLUSION

The impairment of uterine drainage increased periglandular fibrosis in endometrium and decreased pregnancy rates.

## REFERENCES

1. Colahan, P.T., Mayhew, A.M.M. and Moore, J.N.- *Manual of Equine Medicine and Surgery*, Mosby, Inc.1999; 312-359.
2. Hoffmann, C., Bazer, F.W., Klug, E., Allen, W.R., Aupperle, H., Ellenberger, C., Schoon, H.A.- Morphofunctional studies regarding the pathogenesis of the equine endometrosis with special emphasis of uterine secretions-preliminary results. *Pferdeheilkunde*. 2003; 19 : 666-669.
3. Katila, T. Onset and duration of uterine inflammatory response of mares after insemination with fresh semen. *Biology of Reproduction*. Monograph. 1995; 1: 515-517.
4. Kenney, R.M. Cyclic and pathological changes of the mare endometrium as detected by biopsy, with a note on early embryonic death. *Journal of the American Veterinary Medical Association*. 1978; 172:241-262.
5. Kenney, R.M., Doig, P.A. Equine endometrial biopsy. In: *Morrow D.A. (Ed.) Current therapy in Theriogenology*. W.B. Saunders.1986; 723-729.
6. Oddsdottir, C., Bjornsdottir, S., Riley, S.C., Watson, E.D. Development of endometrial fibrosis in the mare. *Reproduction in Domestic Animals*, Willey-Blackwell 2008; 43:25.
7. Ricketts, S. W., Alonso, S. Assessment of the breeding prognosis of mares using paired endometrial biopsy techniques. *Equine Veterinary Journal* 1991; 23:3:185–188.
8. Squires, E.L., Barness, C.K., Rowley, H.S., McKinnon, A.O., Pickett, B.W., Shideler, R.K. Effect of uterine fluid and volume of extender on fertility. In: *Proceedings of the 35<sup>th</sup> Meeting of the American Association of Equine Practitioners*, Elsevier. 1989; 25-30.
9. Troedsson, M.H.T. Diseases of the uterus. In: *Robinson, N.D. (Ed.), Current therapy on Equine Medicine*. W.B Saunders. 1997; 517-523.